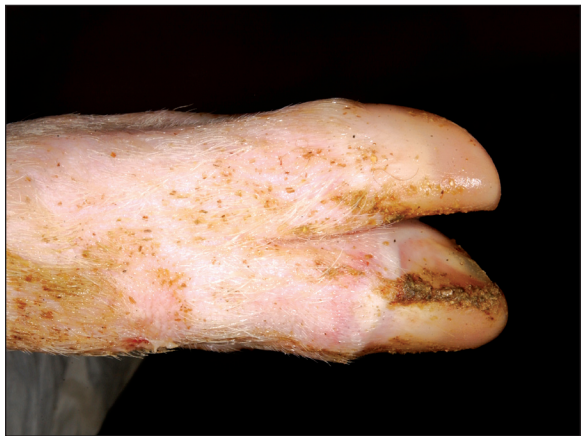

FOOT AND MOUTH DISEASE IN PIGS

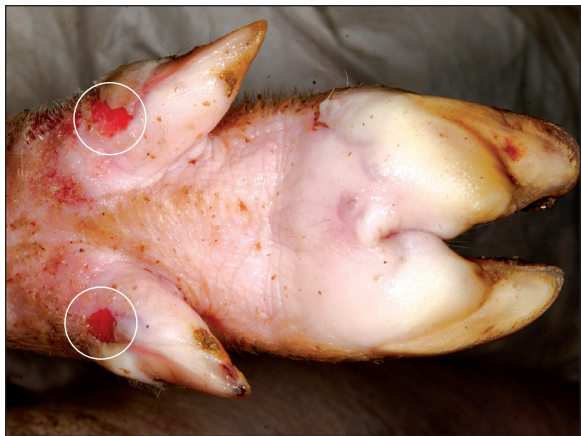PROGRESSION OF LESIONS

DAYS 2, 4, AND 6 POST-INFECTION

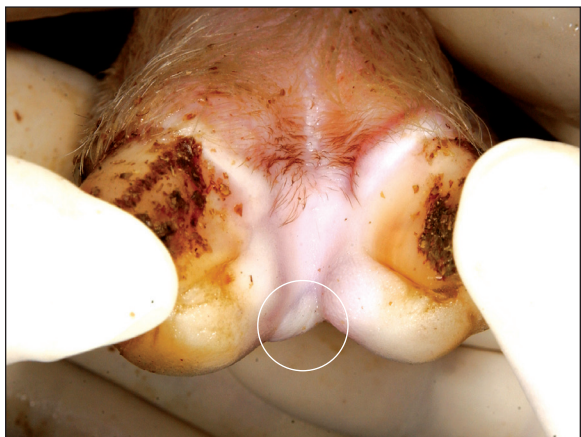
DAY 2



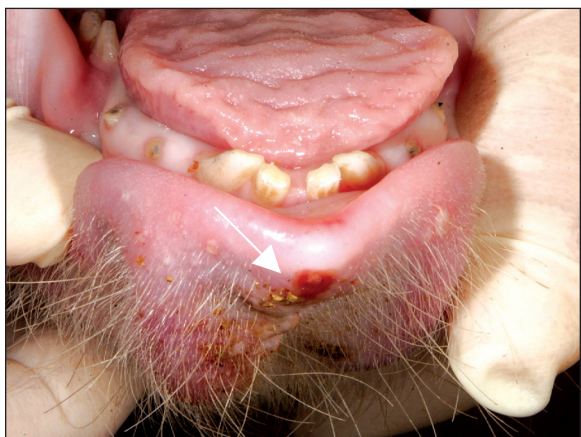
Blanched coronary band



Vesicles of hoof pads and ruptured vesicles of dewclaws

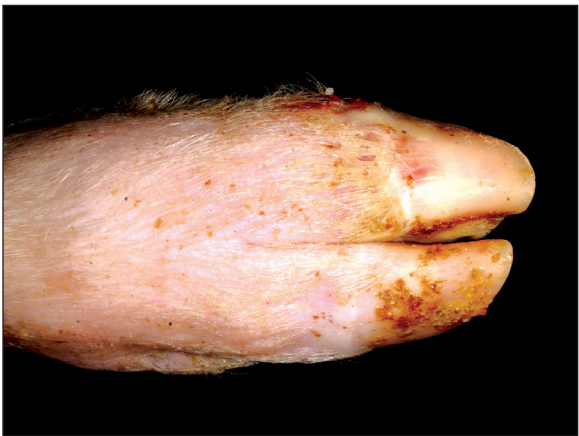

Vesicle in interdigital area

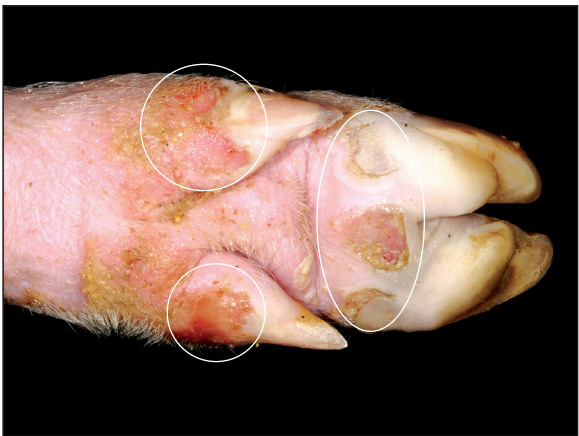

Erosion of tip of lower lip

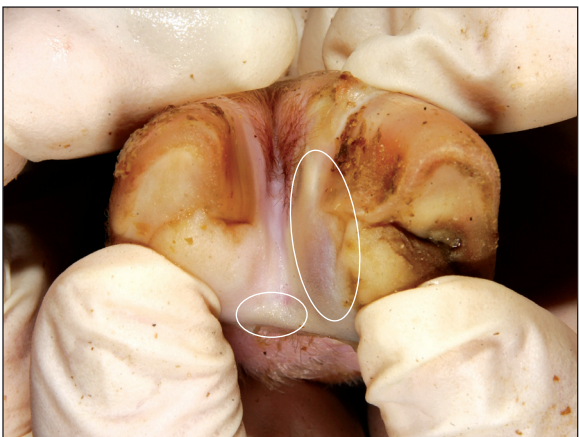
DAY 4



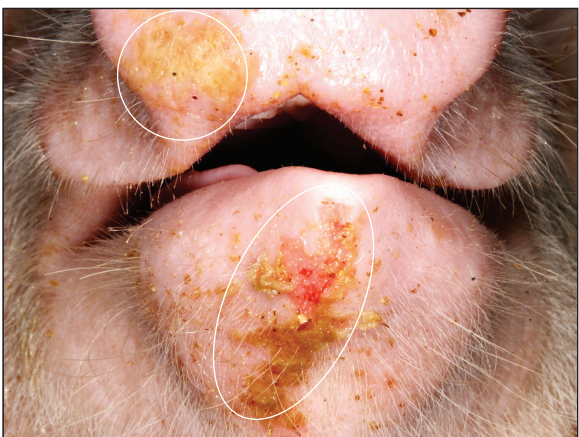Blanched coronary band



Ulcerations and erosions from ruptured vesicles

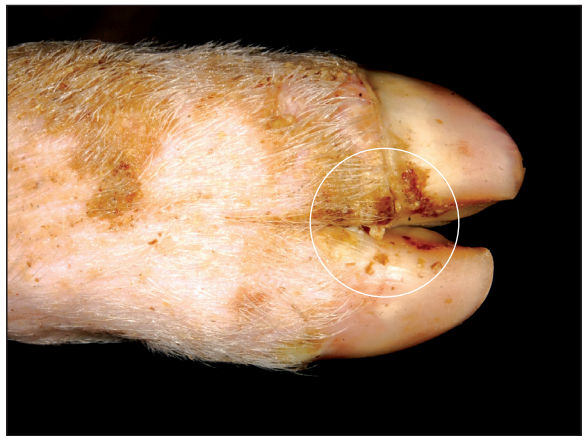

Vesicle in interdigital area and swollen coronary band

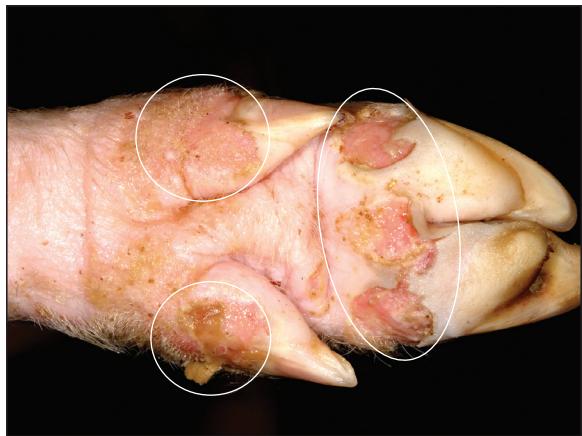


Erosion of lower lip and snout with fibrin

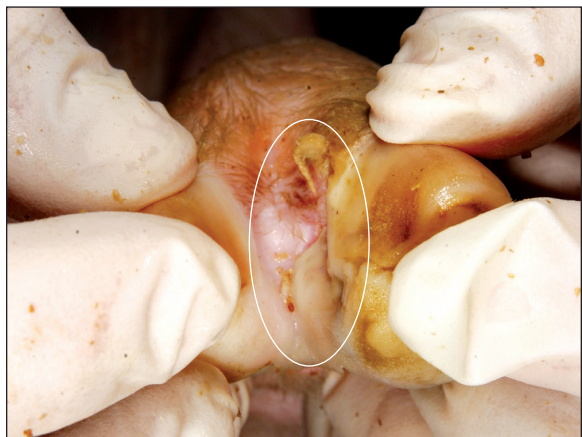
DAY 6



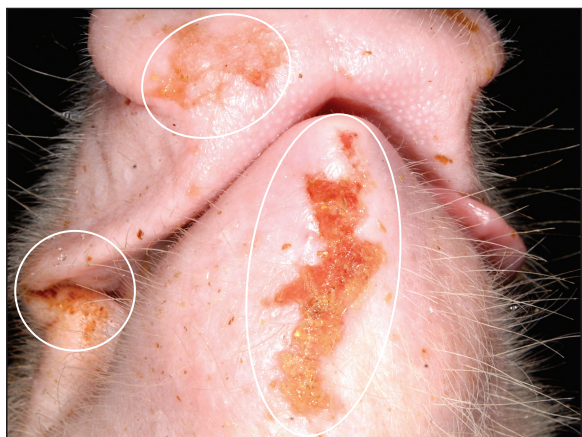Necrosis of coronary band with crusting



Multifocal deep ulcers, hoof pad and dewclaws at the coronary band



Interdigital ulceration at coronary band



Erosion with fibrin deposition

If you suspect a Foreign Animal Disease

Call your State Animal Health Official (SAHO) or Area Veterinarian-In-Charge (AVIC) to report your concerns. If you do not have access to the contact information of the SAHO or the AVIC at your location, you can call 866-536-7593, to reach the office of the AVIC for your state. You can also call the USDA APHIS Veterinary Services National Center for Animal Health Emergency Management at 800-940-6524 (24 hours) for assistance.

Photo Credit: USDA APHIS Foreign Animal Disease Diagnostic Laboratory and the Department of Homeland Security Visual Information Service at Plum Island Animal Disease Center