

S
l
i
d
e

1

Echinococcosis

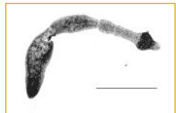
Echinococcosis
Hydatidosis
Hydatid Disease

S
l
i
d
e

2

Overview

- Organism
- History
- Epidemiology
- Transmission
- Disease in Humans
- Disease in Animals
- Prevention and Control



Center for Food Security and Public Health, Iowa State University, 2012

In today's presentation we will cover information regarding the organism that causes echinococcosis and its epidemiology. We will also talk about the history of the disease, how it is transmitted, species that it affects (including humans), and clinical and necropsy signs observed. Finally, we will address prevention and control measures, as well as actions to take if echinococcosis is suspected.

[Photo: *Echinococcus multilocularis*. Source: Centers for Disease Control and Prevention]

S
l
i
d
e

3


THE ORGANISM

S
l
i
d
e

4

The Organism

- Cestode parasites
 - Family Taeniidae
- Currently recognized species
 - *Echinococcus granulosus*
 - *Echinococcus multilocularis*
 - *Echinococcus vogeli*
 - *Echinococcus oligarthrus*
 - *Echinococcus shiquicus*



Center for Food Security and Public Health, Iowa State University, 2012

Echinococcosis is caused by several species of *Echinococcus*, tiny cestode parasites in the family *Taeniidae*. Currently recognized species include *Echinococcus granulosus*, *E. multilocularis*, *E. vogeli*, *E. oligarthrus* and *E. shiquicus*.

[Photo: Photomicrograph revealing internal morphology of an adult cestode, *Echinococcus granulosus*, found in a dog. Source: CDC Public Health Image Library]

S
l
i
d
e

5

The Organism

- *Echinococcus granulosus*
 - Cystic echinococcosis
 - Unilocular echinococcosis
 - Cystic hydatid disease
- Multiple species and strains
- *E. granulosus sensu lato*
 - General term for all species and strains

Center for Food Security and Public Health, Iowa State University, 2012

E. granulosus causes a type of echinococcosis known as cystic echinococcosis, unilocular echinococcosis or cystic hydatid disease. This species has traditionally been divided into strains, named G1 to G10, which have a degree of host adaptation and are maintained in distinct cycles. Some strains have been proposed as species. *E. granulosus sensu lato* (*E. granulosus s. l.*) can be used as a general term for all of the species and strains.

S
I
d
e
6

***E. granulosus* Strains**

Strain	Host	Species/Name
G1, G2	Sheep	<i>E. granulosus sensu stricto</i>
G3	Buffalo	<i>E. granulosus sensu stricto</i>
G4	Horses	<i>E. equinus</i>
G5	Cattle	<i>E. ortleppi</i>
G6	Camels	<i>E. canadensis</i>
G7	Pig	<i>E. canadensis</i>
G8	Cervids	<i>E. canadensis</i>
G10	Cervids	<i>E. canadensis</i>

Center for Food Security and Public Health, Iowa State University, 2012

Two strains - the G1 sheep strain and the G2 Tasmanian sheep strain, primarily use sheep as their intermediate host, but can also infect a variety of other species. Together with the G3 buffalo strain, the G1 and G2 strains are called *Echinococcus granulosus sensu stricto*. The G4 strain, which occurs only in equid intermediate hosts, does not mature in media that support the growth of the sheep strains, and does not seem to be zoonotic, is called *E. equinus*. G5 cattle strain has been designated *Echinococcus ortleppi*. It is unusual in that it regularly uses cattle, which are rarely affected by other strains, as intermediate hosts. The G6 camel strain, G7 pig strain, a poorly characterized G9 strain, and two cervid strains, G8 and G10, might comprise another species called *E. canadensis*. The G9 strain has been reported only from human cases in Poland, and some authors consider it to be a variant of the G7 pig strain. A lion strain has been reported from Africa. Unlike most *Echinococcus* species, which have canids as their primary definitive hosts, this strain mainly uses felids. It has also been called *E. felidis*. Some strains are still poorly characterized, and additional strains probably exist.

S
I
d
e
7

The Organism

- *E. multilocularis*
 - Alveolar echinococcosis
 - Alveolar hydatid disease
 - Multilocular echinococcosis
 - Multivesicular hydatidosis
- Multiple strains
 - Less distinct than *E. granulosus s.l.*
 - *E. shiquicus* a distinct species?

Center for Food Security and Public Health, Iowa State University, 2012

E. multilocularis causes a type of echinococcosis known as alveolar echinococcosis, alveolar hydatid disease, multilocular echinococcosis or multivesicular hydatidosis. It has been divided into Eurasian, North American and Chinese ‘strains,’ which are less distinct than those of *E. granulosus s.l.* One group of organisms has been proposed as a distinct species, *Echinococcus shiquicus*. *E. shiquicus* has been isolated only from small mammals and Tibetan foxes (*Vulpes ferrilata*) from the Tibetan Plateau region of China. Whether it should receive its own species designation is still uncertain.

S
I
d
e
8

The Organism

- *Echinococcus vogeli* and *Echinococcus oligarthrus*
 - Polycystic echinococcosis
 - Unicystic echinococcosis


Center for Food Security and Public Health, Iowa State University, 2012

Infections with *Echinococcus vogeli* and *Echinococcus oligarthrus* are usually known as polycystic echinococcosis (or neotropical polycystic echinococcosis), from the form of the disease in intermediate hosts. Because *E. oligarthrus* has been reported only as one or more discrete cysts in humans, this disease has also been called unicystic echinococcosis.

S
I
d
e
9

**The Organism:
Zoonotic Species**

- G1 (sheep strain)
E. granulosus s.l.
 - Most frequent cause of disease in humans
- Other species may be important regionally



Center for Food Security and Public Health, Iowa State University, 2012

The G1 sheep strain of *E. granulosus s. l.*, which is particularly widespread, is the most frequent cause of disease in humans. Regionally, other *E. granulosus s. l.* strains/ species may be more important than G1. Some strains or species of *Echinococcus* affect people infrequently, or grow relatively slowly and are less likely to cause disease. *E. oligarthrus* seems to be extremely rare in people, and *E. equinus* (*E. granulosus* strain G4) has not been reported to be zoonotic in the literature.

[Photo: Flock of sheep. Source: USDA ARS]

S
l
i
d
e

1
0

EPIDEMIOLOGY

S
l
i
d
e

1
1
1

**Distribution:
*E. granulosus s.l.***

Strain/Species	Geographic Distribution
G1	Europe, Middle East, Africa, Australia, New Zealand, North America, South America
G2	Asia, South America, Africa, Europe
G3	Asia, Europe, South America
G4	Europe, Middle East, Africa
G5	Europe, Africa, Asia, South America
G6	Middle East, Africa, Asia, South America
G7	Europe, Russia, South America, Mexico
G8, G10	North America, Eurasia

Center for Food Security and Public Health, Iowa State University, 2012

E. granulosus s. l. occurs worldwide, with the exception of a few countries such as Iceland and Greenland. Within an area, its distribution may be focal. Each strain/species has a distinct geographic range. The G1 sheep strain is cosmopolitan; it has been reported in Europe, the Middle East, Africa, parts of Asia, Australian, New Zealand, and North and South America. In North America, this strain has mainly been reported from the western U.S. It also occurs in Mexico. The G2 Tasmanian sheep strain was once thought to be limited in its geographic range, but it has now been identified in Asia, South America, Africa and Europe, as well as in Tasmania. The G3 strain has been reported from Asia, Europe and South America, and the G4 strain (*E. equinus*) is known to occur in Europe, the Middle East and Africa. The G5 cattle strain (*E. ortleppi*) has been documented in Europe, Africa, parts of Asia, and South America, and the G6 camel strain is known to occur in the Middle East, Africa, Asia and South America. The G7 pig strain has been identified in Europe, Russia, South America and Mexico, while the closely related G9 strain has been reported only from Poland. The G8 and G10 cervid strains have been found in North America, mainly in Canada and some northern U.S. states, as well as in Eurasia. *E. felidis* (the “lion strain”) is thought to occur only in Africa. Molecular techniques have recognized many strains/species in new areas during the last 5-10 years, and these geographic ranges are probably incomplete.

S
l
i
d
e

1
2

Distribution

- *E. multilocularis*
 - Northern hemisphere
 - Eurasia, Europe, North America
- *E. vogeli, E. oligarthrus*
 - Central and South America
- *E. shiquicus*
 - China

Center for Food Security and Public Health, Iowa State University, 2012

E. multilocularis is found primarily in the northern hemisphere. This parasite is either expanding its geographic range or it is being identified in new areas due to increased surveillance. *E. multilocularis* has been reported in much of northern and central Eurasia eastward to Japan. It is widely distributed in continental Europe. This organism also occurs in North America, where it is primarily found in Canada, Alaska and the north central U.S. from Montana to central Ohio. *E. vogeli* and *E. oligarthrus* have been found only in Central and South America, and *E. shiquicus* has been identified on the Tibetan plateau in China.

S
l
i
d
e

1
3

TRANSMISSION

S
l
i
d
e

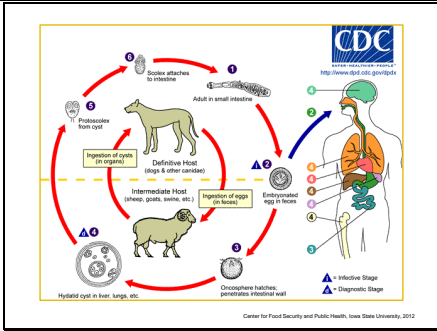
1
4

- Transmission**
- Indirect life cycle
 - Definitive hosts ingest cysts in tissues of intermediate hosts
 - Cysts develop into tapeworms
 - Gravid proglottids or eggs shed in feces by definitive host
 - Eggs ingested by intermediate hosts
- Center for Food Security and Public Health, Iowa State University, 2012

Echinococcus species have an indirect life cycle, and must develop in both an intermediate and a definitive host. In many cases, the parasite cycles through specific predators or scavengers, and their prey. Definitive hosts become infected when they ingest cysts (metacestodes) in the tissues of the intermediate hosts. The cysts develop into tapeworms, which mature in the host's small intestine. Gravid proglottids or eggs are shed in the feces, and are immediately infective. Under ideal conditions, eggs remain viable for several weeks or months in pastures or gardens, and on fomites. They survive best under moist conditions and in moderate temperatures. The intermediate hosts include a large number of domesticated and wild animals, particularly herbivores. Humans can also be infected. If an intermediate host ingests the eggs, the larvae are released, penetrate the intestinal wall, and are carried in blood or lymph to the target organs.

S
l
i
d
e

1
5



Human echinococcosis is caused by the larval stages of cestodes (tapeworms) of the genus *Echinococcus*. The adult *Echinococcus granulosus* (3 to 6 mm long) resides in the small bowel of the definitive hosts, dogs or other canids. Gravid proglottids release eggs that are passed in the feces. After ingestion by a suitable intermediate host (under natural conditions: sheep, goat, swine, cattle, horses, camel), the egg hatches in the small bowel and releases an oncosphere that penetrates the intestinal wall and migrates through the circulatory system into various organs, especially the liver and lungs. In these organs, the oncosphere develops into a cyst that enlarges gradually, producing protoscolices and daughter cysts that fill the cyst interior. The definitive host becomes infected by ingesting the cyst-containing organs of the infected intermediate host. After ingestion, the protoscolices evaginate, attach to the intestinal mucosa, and develop into adult stages in 32 to 80 days.


Image: Life cycle of *Echinococcus*. Source: CDC Division of Parasitic Diseases]

S
l
i
d
e

1
6

**Transmission:
*E. granulosus s.l.***

- Definitive hosts
 - Canids
 - Felids
 - Hyaenids
- Intermediate hosts
 - Herbivores
 - Humans



Center for Food Security and Public Health, Iowa State University, 2012

The definitive hosts for *E. granulosus s. l.* are canids, felids, and hyaenids. *Echinococcus* eggs have a sticky coat that will adhere to an animal’s fur and other objects. Insects such as flies and beetles, or birds, can also act as mechanical vectors. In addition, the shed proglottids may perform rhythmic contractions that help to disperse the eggs widely on pastures.


[Photo: Dogs. Source: Nichollette Rider/CFSPH]

S
l
i
d
e

1
7

**Transmission:
*E. multilocularis***

- Definitive hosts
 - Wild carnivores (e.g., fox)
 - Domestic dogs and cats
- Intermediate hosts
 - Small mammals (rodents)
 - Domesticated mammals
 - Humans



Center for Food Security and Public Health, Iowa State University, 2012

The life cycle and transmission of *E. multilocularis* is very similar to that of *E. granulosus s. l.*. Although this species usually cycles in wildlife, with a variety of carnivores serving as definitive hosts, the adult tapeworms can also mature in domesticated dogs and cats. The intermediate hosts are usually small mammals, particularly rodents, but domesticated animals and humans can also be infected. Dogs can act as intermediate hosts, either by autoinfection or by ingesting eggs shed in the feces of another definitive host, such as a fox.

[Photo: (Top) Swift fox. Source: U.S. Fish and Wildlife Service; (Bottom) White-footed mouse. Source: John White/Maryland Department of Natural Resources]

S
l
i
d
e

1
8

Transmission

<ul style="list-style-type: none"> • <i>E. vogeli</i> <ul style="list-style-type: none"> - Definitive hosts <ul style="list-style-type: none"> • Bush dogs • Domestic dogs - Intermediate hosts <ul style="list-style-type: none"> • South American rodents (e.g., pacas) 	<ul style="list-style-type: none"> • <i>E. oligarthus</i> <ul style="list-style-type: none"> - Definitive hosts <ul style="list-style-type: none"> • Wild felids - Intermediate hosts <ul style="list-style-type: none"> • Rodents
--	--

Center for Food Security and Public Health, Iowa State University, 2012

The definitive hosts for *E. vogeli* are bush dogs (*Speothos venaticus*) and the intermediate hosts are South American rodents, especially pacas (*Cuniculus paca*). Dogs, which may be given the entrails from pacas after a hunt, can also act as definitive hosts. The definitive hosts for *E. oligarthus* are wild felids, and the intermediate hosts are rodents.

S
l
i
d
e


1
9

Zoonotic Transmission

- Humans act as *intermediate* hosts
- Ingest tapeworm eggs shed by definitive hosts
 - Contaminated fruits, vegetables, herbs, water

Center for Food Security and Public Health, Iowa State University, 2012

Humans act as intermediate hosts for *Echinococcus* spp., and are infected when they ingest tapeworm eggs from the definitive host. The eggs may be eaten in foods such as vegetables, fruits or herbs, or drunk in contaminated water. They can also stick to the hands when a person pets an infected dog or cat, handles a wild animal or its carcass, or touches contaminated soil and vegetation. Uninfected pets may carry the eggs on their fur if they contact the feces of infected wild hosts. This is probably more common in dogs, which may roll in feces.

S l i d e 2 0	<p>DISEASE IN HUMANS</p>	
S l i d e 2 1	<p>Disease in Humans</p> <ul style="list-style-type: none"> • Incubation period <ul style="list-style-type: none"> - Month to years - 20 to 30 years documented for cysts that grow slowly and are not in a critical location • Clinical signs <ul style="list-style-type: none"> - Depend on size, number and location of metacestodes <p style="text-align: right; font-size: small;">Center for Food Security and Public Health, Iowa State University, 2012</p>	<p>The incubation period for echinococcosis varies from months to years. It can be as long as 20-30 years, if the cyst grows slowly and is not in a critical location. The symptoms of echinococcosis depend on the size, number and the location of the metacestodes. Until the cysts become large enough to damage adjacent tissues and organs, they are usually asymptomatic. The clinical signs are those of a mass lesion.</p>
S l i d e 2 2	<p>Disease in Humans: <i>E. granulosus s.l.</i></p> <ul style="list-style-type: none"> • May be asymptomatic • Usually one cyst present • Cyst location <ul style="list-style-type: none"> - 60 to 70% in liver - 20 to 25% in lungs • Symptoms dependent on cyst location <p style="text-align: right; font-size: small;">Center for Food Security and Public Health, Iowa State University, 2012</p>	<p><i>E. granulosus s. l.</i> cysts can remain asymptomatic for many years. They are usually well tolerated until they cause pressure on surrounding tissues. The symptoms resemble those of a slowly growing tumor. Although most people have only one cyst, multiple cysts can be found. Approximately 60-70% of <i>E. granulosus s. l.</i> cysts occur in the liver and 20-25% in the lungs. The remaining cysts can be found almost anywhere in the body including the bones, kidneys, spleen, muscles, CNS and behind the eye. Depending on the location, some cysts can become very large and may contain up to several liters of fluid. Others in critical locations such as the brain become symptomatic when they are still small. Secondary cystic echinococcosis occurs when a cyst leaks or ruptures; dissemination is seen mainly in the abdominal cavity. Leakage of the cyst fluid can also cause allergic reactions including shaking chills and/or fever, asthma, pruritus, urticaria or life-threatening anaphylaxis Other symptoms vary with the location(s) of the cysts. <i>E. granulosus s. l.</i> cysts can also be asymptomatic throughout the individual's life, and may be incidental findings at surgery or autopsy. Some cysts may die and not develop further.</p>
S l i d e 2 3	<p>Disease in Humans: <i>E. multilocularis</i></p> <ul style="list-style-type: none"> • Cysts usually found in liver • Cysts not enclosed within membrane <ul style="list-style-type: none"> - Invade surrounding tissues - Disease is progressive and malignant • May be asymptomatic if cyst dies early in development <div style="text-align: right;">  </div> <p style="text-align: right; font-size: small;">Center for Food Security and Public Health, Iowa State University, 2012</p>	<p>The primary lesion of <i>E. multilocularis</i> is almost always in the liver, and the course of the disease is slow. During the early stages, the infection is usually asymptomatic. Larger tumors cause hepatomegaly and epigastric pain. Ascites, malnutrition, jaundice and signs of hepatic failure may occur in later stages of disease. Splenomegaly can also be seen. <i>E. multilocularis</i> cysts are very dangerous as they are not enclosed within a membrane and invade tissues by budding outward; alveolar hydatidosis is progressive and malignant. The cysts can spread to nearby organs and metastasize to the brain, lungs, mediastinum and other organs or tissues. Sometimes, the primary cyst dies early in its development, and remains asymptomatic. [Photo: Human, liver. Multiple thin-walled hydatid cysts project from the capsular surface of the liver. Source: Armed Forces Institute of Pathology/CFSPH]</p>

S
I
d
e
2
4

Disease in Humans:
E. vogeli, E. oligarthrus

- Cysts usually originate in liver
 - Can spread to nearby organs/tissues
- Symptoms dependent on cyst location

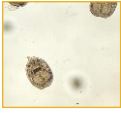
Center for Food Security and Public Health, Iowa State University, 2012

E. vogeli tends to occur initially in the liver; however, the cysts are invasive and can spread to nearby organs and tissues. The clinical signs resemble alveolar echinococcosis. Common symptoms with liver involvement include hepatomegaly, abdominal distension, weight loss, abdominal pain, jaundice and anemia. Palpable masses, which may or may not be painful, can be present in the liver or abdomen, and there may be signs of portal hypertension or biliary obstruction. Coughing, chest pain and hemoptysis can be seen if the lung is involved, and the rupture of esophageal varices can result.

S
I
d
e
2
5

Diagnosis

- Imaging techniques
 - Ultrasound, radiology, MRI, CT
- Serology
- Biopsy
- Detection of protoscolices
 - Cyst fluid, sputum
- PCR



Center for Food Security and Public Health, Iowa State University, 2012

In humans, echinococcosis is diagnosed mainly with imaging techniques such as ultrasonography, radiology, magnetic resonance imaging (MRI) or CT scanning, supported by serology. Serological tests used in humans include enzyme-linked immunosorbent assays (ELISAs), indirect immunofluorescence, indirect hemagglutination, immunoblotting and latex agglutination. Some people with cysts do not develop detectable antibodies. False positives, which include cross-reactions with other taeniid cestodes, are also possible. Biopsies can also be used in diagnosis, but there is risk of cyst leakage or rupture, and antiparasitic drugs must be given concurrently. Ultrasonography-guided fine-needle puncture can distinguish cysts from tumors, abscesses and other lesions. The cyst fluid recovered with this technique can be examined for protoscolices and other evidence of the parasites. It may also be tested for *Echinococcus* antigens with an antigen-detection ELISA, or for parasite DNA using polymerase chain reaction (PCR) assays. When the lungs are affected, protoscolices might be found in sputum or bronchial washings. *Echinococcus* species can be distinguished by PCR followed by sequencing or restriction fragment length polymorphism analysis. Both nuclear and mitochondrial genes are used in differentiating species/ strains. Cysts from different species can also be distinguished by the morphology of the protoscolices, if they are present. In humans, some cysts are “sterile”; they do not produce protoscolices. [Photo: Under a low magnification of only 100X, this photomicrograph revealed three *Echinococcus* sp. protoscolices, which had been liberated from a hydatid cyst. Rupture of these cysts releases these larval protoscolices, and a condition known as “hydatid sand”. Source: CDC Public Health Image Library]

S
I
d
e
2
6

Treatment

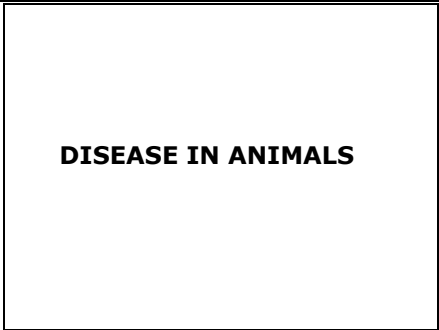- Surgical removal of cysts
 - May not be possible to remove entire cyst depending on size and location
- Anti-parasitics
- Wait-and-see
 - Small, inactive cysts
- Liver transplant

Center for Food Security and Public Health, Iowa State University, 2012

Cysts are often removed surgically. The success rate varies with the species of *Echinococcus* and the location and size of the cyst(s). In some situations, particularly with *E. multilocularis* or *E. vogeli* infections, it may not be possible to remove the entire cyst. Long-term post-surgical treatment with antiparasitic drugs such as albendazole or mebendazole may shrink or destroy the organism, help prevent it from regrowing and/ or ameliorate the symptoms. Drug treatment is also an alternative to surgery in some cases. Another treatment option is the removal of most of the cyst contents and the introduction of an anthelmintic chemical into the cyst under ultrasonographic guidance (PAIR - puncture, aspiration, injection, and re-aspiration). Sometimes (e.g., small inactive cysts in certain locations) a “wait and see” approach might also be appropriate. In severe cases of alveolar echinococcosis, a liver transplant may be an option.

S
l
i
d
e

2
7



S
l
i
d
e

2
8

Disease in Animals

- Incubation period
 - Months to years
 - 20 to 30 years documented
- Clinical signs
 - Depend on cyst size, number, location
 - Often asymptomatic until cysts invade adjacent tissues/organs

Center for Food Security and Public Health, Iowa State University, 2012


The incubation period for echinococcosis varies from months to years. It can be as long as 20-30 years, if the cyst grows slowly and is not in a critical location. The symptoms of echinococcosis depend on the size, number and the location of the metacestodes. Until the cysts become large enough to damage adjacent tissues and organs, they are usually asymptomatic. The clinical signs are those of a mass lesion.

S
l
i
d
e

2
9

**Clinical Signs:
Definitive Hosts**

- Usually asymptomatic
 - Even with heavy parasite burden
- Disease rarely occurs
 - Enteritis
 - Diarrhea



Center for Food Security and Public Health, Iowa State University, 2012

Echinococcus spp. are usually carried asymptotically in their definitive hosts. Large numbers of parasites may be able to cause enteritis and diarrhea, but this seems to be rare; thousands of adult parasites have been found in asymptomatic dogs and foxes.

[Photo: Baby red fox. Source: U.S. Fish and Wildlife Service National Digital Library]

S
l
i
d
e

3
0

**Clinical Signs:
Intermediate Hosts**

- *E. granulosus s.l.*
 - Cysts grow slowly
 - Asymptomatic until surrounding tissues/organs become involved
 - Livestock typically slaughtered before this occurs
 - Liver and lung most affected

Center for Food Security and Public Health, Iowa State University, 2012


There is little information on natural infections with *E. granulosus s. l.* in domesticated animals. The cysts grow slowly and are usually asymptomatic until they are large enough to put pressure on adjacent tissues and organs. Livestock are often slaughtered before this occurs. If clinical signs are seen, they are those of a mass lesion and vary with the organ affected. Most cysts are found in the liver and lungs, but they may also occur in many other organs. Symptoms that have been reported occasionally in sheep include hepatic disorders with ascites and jaundice, as well as bronchopneumonia, heart failure, poor growth, weakness and lameness.

S
l
i
d
e

3
1

**Clinical Signs:
Intermediate Hosts**

- *E. multilocularis*
 - Cysts most often found in liver
 - Metastatic lesions occur in other organs
 - Lungs, brain
 - Rodents may die within weeks of infection
 - Multiple organs affected



Center for Food Security and Public Health, Iowa State University, 2012

E. multilocularis usually affects the liver, but, in more advanced cases, metastatic lesions may be found in other organs including the lungs and brain. The tumor-like cysts can kill rodents within a few weeks of infection. Symptomatic infections, associated primarily with lesions in the liver and abdominal cavity, have also been reported in dogs and nonhuman primates. In eleven dogs, progressive abdominal enlargement, without severe clinical signs, was the most consistent sign. Ascites, abdominal masses, hepatomegaly, dyspnea, intermittent diarrhea, nausea, vomiting and weight loss have also been reported. In advanced disease, cysts may seed multiple organs, causing severe illness and death within weeks. Asymptomatic hepatic lesions have also

been reported in pigs and horses, as an incidental finding at necropsy.

[Photo: Gross pathology of cotton rat infected with *Echinococcus multilocularis*. Source: CDC Public Health Image Library]

S
I
i
d
e
3
2

**Clinical Signs:
Intermediate Hosts**

- *E. vogeli*, *E. oligarthrus*
 - Not documented in domesticated animal intermediate hosts
 - Zoo outbreaks
 - Nutrias
 - Nonhuman primates


Center for Food Security and Public Health, Iowa State University, 2012

E. oligarthrus has not been documented in domesticated animal intermediate hosts. Two outbreaks caused by *E. vogeli*, one affecting nutrias and the other in nonhuman primates, have been reported in zoos. Orangutans and gorillas developed severe clinical signs including very pendulous abdomens. A number of animals died or had to be euthanized. In pacas, *E. vogeli* does not seem to be symptomatic unless the cysts become very large.

S
I
i
d
e
3
3

Post Mortem Lesions

- No lesions in definitive hosts
- Intermediate hosts
 - Cysts grossly apparent
 - *E. granulosus s.l.*
 - Fluid-filled
 - Fibrous wall
 - Liver, lungs, other internal organs
 - *E. multilocularis*
 - Liver, lungs, CNS
 - Multilocular, semisolid
 - Lobulated



Center for Food Security and Public Health, Iowa State University, 2012

There are no lesions in the definitive hosts. Adult *Echinococcus* tapeworms are tiny, usually vary from 1.2 mm to 7 mm in length, and are attached to the small intestine. Most species have five or fewer segments, although some individual specimens may have up to seven. In the intermediate hosts, the cysts are grossly apparent in tissues at necropsy. *E. granulosus s. l.* metacestodes are usually individual fluid-filled cysts, surrounded by a fibrous wall. Most cysts are 1-7 cm in diameter, but some can become much bigger. Although most cysts occur in the liver, some may be found only in the lungs or, less often, in other internal organs including the bones. *E. multilocularis* metacestodes occur initially in the liver, but they can metastasize to other organs, particularly the lungs and CNS. These multilocular cysts have a semisolid matrix and resemble malignant tumors. They may be firm and lobulated or contain viscous fluid, and can contain many scattered transparent cysts of a few millimeters to centimeters in diameter. The center of the lesion may be necrotic. In their natural hosts, the cysts of *E. vogeli* and *E. oligarthrus* can occur singly or as aggregates. Exogenous proliferation occurs in nonhuman primates and possibly in other aberrant hosts.

[Photo: Skunk, liver. The inner surface of the cyst is lined by hydatid sand, and the cyst is surrounded by a thick capsule of fibrous connective tissue. Source: Iowa State University, College of Veterinary Medicine/CFSPH]

S
I
d
e
3
4

Diagnosis: Definitive Hosts

- Routine fecal testing not appropriate
 - Cannot differentiate from *Taenia* spp.
 - Tiny proglottids in feces not noticeable
- ELISA
 - Screening for definitive hosts
- PCR
 - Fecal samples
- Morphology

Center for Food Security and Public Health, Iowa State University, 2012

Infected dogs and cats cannot be identified by routine fecal testing: *Echinococcus* eggs are morphologically indistinguishable from *Taenia* spp., and the tiny proglottids are rarely noticed in feces. ELISAs that detect *Echinococcus* antigens in fecal samples (coproantigen ELISA) can be used to screen definitive hosts. This assay can detect both prepatent and patent infections. A PCR assay designed for fecal samples (copro-DNA assay) is mainly used to confirm the infection or to identify eggs from the feces. *Echinococcus* adults or their proglottids can also be found in the definitive host after purgation with arecoline compounds. Direct examination of the intestines at necropsy may be used in some circumstances (e.g., in research or if the animal has died). *Echinococcus* species can be distinguished by PCR followed by sequencing or restriction fragment length polymorphism analysis. The parasites also differ in their morphology and can be identified by experts.

S
I
d
e
3
5

Diagnosis: Intermediate Hosts

- Usually discovered at necropsy
- Histology
- Antigen detection
- PCR
- Serology
 - Not generally used in domestic animals
 - Poor response in usual intermediate hosts

Center for Food Security and Public Health, Iowa State University, 2012

In animal intermediate hosts, echinococcosis is mainly diagnosed at necropsy, or occasionally at surgery. Fine needle biopsy might also be used in live animals, but the possibility of cyst leakage or rupture (similarly to humans) should be considered. Metacestodes and protoscolices in cyst fluid or tissues can be identified by histology. Antigen detection or PCR can also be done. DNA techniques are particularly useful for distinguishing *Echinococcus* species or strains (especially among *E. granulosus s.l.*), or for identifying small, degenerated or calcified lesions. Ultrasound and other imaging methods may be helpful in some species such as dogs, but a biopsy or exploratory laparotomy might be required for a definitive diagnosis. Serological tests are not generally used for diagnosis in domesticated animals. A species of *Echinococcus* sometimes induces relatively poor serological responses in its usual intermediate hosts. ELISA tests may be useful for serological diagnosis in infected sheep flocks, but they are not reliable in individual animals. Serology might also be of some use, in conjunction with imaging techniques, in dogs with cysts; however, antibodies can be caused by previous infections with the adult tapeworms, and cross-reactions can occur with *Taenia* species.


S
I
d
e
3
6

Treatment

- Anthelmintic drugs
 - Praziquantel
- Surgery
 - Intermediate hosts
 - Follow with long term daily anti-parasitics

Center for Food Security and Public Health, Iowa State University, 2012

In the definitive host, *Echinococcus* spp. can be treated with anthelmintic drugs. Praziquantel, which is effective against both juvenile and adult *Echinococcus* parasites, is often used. In intermediate hosts, surgery is often the treatment of choice. Long-term anthelminthic treatment may also suppress some cysts. Long term daily albendazole treatment, after surgical resection of the cyst masses, has suppressed parasite growth in some dogs with *E. multilocularis* cysts.

<p>S I d e 3 7</p>	<p style="text-align: center;">PREVENTION AND CONTROL</p>	
<p>S I d e 3 8</p>	<p style="text-align: center;">Prevention in Humans</p> <ul style="list-style-type: none"> • Control echinococcosis in domestic animals <ul style="list-style-type: none"> - Don't feed livestock entrails to dogs - Don't allow dogs and cats to hunt - Regularly test and/or treat animals allowed outside <p style="text-align: right; font-size: small;">Center for Food Security and Public Health, Iowa State University, 2012</p>	<p>Controlling <i>Echinococcus</i> spp. that occur in domesticated animal cycles reduces human exposure. In particular, dogs should not be fed the entrails from livestock at slaughter. Because dogs and cats can also be infected from parasites in wildlife cycles, they should not be allowed to hunt wild animals, or be fed any tissues from these species. In endemic areas, regular testing and/or treatment is advisable in animals allowed outside.</p>
<p>S I d e 3 9</p>	<p style="text-align: center;">Prevention in Humans</p> <ul style="list-style-type: none"> • Minimize risk of egg ingestion <ul style="list-style-type: none"> - Wash fruits and vegetables - Wash hands frequently - Avoid untreated water sources - Do not handle wild carnivores or their carcasses - Thoroughly cook meat before eating  <p style="text-align: right; font-size: small;">Center for Food Security and Public Health, Iowa State University, 2012</p>	<p>It is difficult to completely prevent exposure to <i>Echinococcus</i> spp. eggs from wild animals; however, food safety precautions, combined with good hygiene, can be helpful. All fruits and vegetables, particularly those picked in the wild, should be washed thoroughly to remove any eggs. Fences should be placed around vegetable gardens to keep animals, especially dogs and other canids, away. The hands should always be washed after handling pets, farming, gardening or preparing food, and before eating. Untreated water from sources such as lakes may also contain <i>Echinococcus</i> eggs, and should be avoided. Wild carnivores, especially canids and felids, should be discouraged from coming close to homes. If these animals or their carcasses must be handled, gloves should be used. In some areas, foxes have been treated with antiparasitic drugs in bait, to decrease the prevalence of <i>E. multilocularis</i>. Meat, particularly canine intestines, should be thoroughly cooked before eating.</p> <p>[Photo: Washing vegetables. Source: CDC Public Health Image Library]</p>
<p>S I d e 4 0</p>	<p style="text-align: center;">Prevention in Humans</p> <ul style="list-style-type: none"> • Wear personal protective equipment • Regular surveillance <ul style="list-style-type: none"> - Laboratory personnel - Children exposed to feces of infected animals • No vaccine <p style="text-align: right; font-size: small;">Center for Food Security and Public Health, Iowa State University, 2012</p>	<p>Anyone who handles the definitive hosts or material that may be contaminated with eggs should use appropriate personal protective equipment. In some countries, <i>Echinococcus</i> spp. must be handled in a BSL-3 laboratory. Regular surveillance with serological tests can be helpful in high-risk populations such as laboratory personnel working with eggs, or children who have been exposed to the feces of infected foxes. The purpose of testing is to detect cysts in the early stages, when they are most treatable. Vaccines are not available for people.</p>

S I d e 4 1	<p style="text-align: center;">Prevention in Animals</p> <ul style="list-style-type: none"> • Regular surveillance • Treat infected animals (dogs) <ul style="list-style-type: none"> – Praziquantel – Multiple doses required • Vaccination <ul style="list-style-type: none"> – Recombinant <p style="text-align: right; font-size: small;">Center for Food Security and Public Health, Iowa State University, 2012</p>	<p>Dogs may be treated with anthelmintic agents before they are allowed to enter <i>Echinococcus</i>-free areas. Praziquantel is often used. One-time treatment is not adequate; definitive hosts often become reinfected if they are re-exposed. Dogs that might be infected should not be allowed onto pastures where livestock may graze. In some countries, foxes have been treated with praziquantel in bait to decrease the incidence of <i>E. multilocularis</i>, and the risk to other species. Eradication or control programs for the <i>E. granulosus</i> sheep/dog cycle have been successful in some areas, particularly on islands such as Iceland, New Zealand and Tasmania. These programs have targeted the parasite in domesticated dogs by regular surveillance, and if necessary, treatment. Education campaigns have also been used, either alone or in conjunction with programs aimed at dogs. The elimination of farm slaughter of sheep reduces the risk that dogs will be infected from this source. A recombinant vaccine for <i>E. granulosus</i> in sheep has been successful in field trials. This vaccine has been licensed to a commercial group in the People’s Republic of China. Models suggest that livestock vaccines would be most effective if combined with testing and treatment of dogs.</p>
S I d e 4 2	<p style="text-align: center;">Additional Resources</p> <ul style="list-style-type: none"> • Center for Food Security and Public Health <ul style="list-style-type: none"> – www.cfsph.iastate.edu • CDC <ul style="list-style-type: none"> – http://www.cdc.gov/parasites/echinococcosis/ • World Health Organization <ul style="list-style-type: none"> – http://www.who.int/neglected_diseases/diseases/echinococcosis/en/index.html/ <p style="text-align: right; font-size: small;">www.cfsph.iastate.edu</p>	
S I d e 4 3	<p style="text-align: center;">Acknowledgments</p> <p>Development of this presentation was made possible through grants provided to the Center for Food Security and Public Health at Iowa State University, College of Veterinary Medicine from the Centers for Disease Control and Prevention, the U.S. Department of Agriculture, the Iowa Homeland Security and Emergency Management Division, and the Multi-State Partnership for Security in Agriculture.</p> <p style="font-size: x-small;"> Authors: Kerry Leedom Larson, DVM, MPH, PhD, DACVPM; Anna Rovid Spickler, DVM, PhD; Anel Pleva, MPH Reviewer: Glenda Dvorak, DVM, MPH, DACVPM </p>	<p>Last reviewed: September 2012</p>