

S
l
i
d
e
1

Cryptococcosis

Torulosis
European blastomycosis
Busse-Buschke's disease

S
l
i
d
e
2

Overview

- Organism
- History
- Epidemiology
- Transmission
- Disease in Humans
- Disease in Animals
- Prevention and Control

In today's presentation we will cover information regarding the organism that causes cryptococcosis and its epidemiology. We will also talk about the history of the disease, how it is transmitted, species that it affects (including humans), and clinical and necropsy signs observed. Finally, we will address prevention and control measures, as well as actions to take if cryptococcosis is suspected.


S
l
i
d
e
3

THE ORGANISM

S
l
i
d
e
4

The Organism

- *Cryptococcus neoformans*
 - Encapsulated yeast
 - Four serotypes
 - Based on capsular antigens
- *Cryptococcus neoformans* var *neoformans*
 - Serotypes A and D
 - Ubiquitous
 - Causes most cases of cryptococcosis in humans, especially those in the immunocompromised



Cryptococcosis is nearly always caused by *Cryptococcus neoformans*, an encapsulated yeast (Division Basidiomycota). Unlike most pathogenic fungi, this organism occurs in the yeast form both in the host and in the environment. The perfect (mycelial) stage of this fungus is called *Filobasidiella neoformans* or *Filobasidiella bacillisporus*. This stage has never been isolated from patients or found in nature; it is only found in the laboratory under certain conditions. *C. neoformans* is surrounded by a large capsule within its hosts and on some culture media. This capsule is important in its resistance to phagocytosis and in the identification of the organism. Strains differ in their virulence for animals and possibly humans, but the immune status of the host seems to be more important than the virulence of the strain. There are four serotypes - A, B, C and D - based on capsular antigens. There are three varieties: *Cryptococcus neoformans* var. *neoformans* comprises serotypes A and D. This organism is ubiquitous and causes most cases of cryptococcosis. In humans, it is an opportunistic pathogen that mainly affects immunocompromised hosts.

[Photo: *Cryptococcus neoformans* stained by Gram's method. Source: Tina Demers and Dr. Graham Beards/Wikimedia Commons]

S
I
d
e
5

The Organism

- *Cryptococcus neoformans* var *gattii*
 - Serotypes B and C
 - Less common in environment
 - Mostly in immunocompetent hosts
- *Cryptococcus laurentii*
 - Rarely causes disease in humans
 - Immunocompromised hosts

Cryptococcus neoformans var. *gattii* comprises serotypes B and C. This variety is less common in the environment than *C. neoformans* var *neoformans*. In humans, it is mainly found in immunocompetent hosts. It has also been isolated from some cases of cryptococcosis in animals including cats, dogs, porpoises and llamas. There are two perfect states of *C. neoformans*: *Filobasidiella neoformans* var *neoformans* is the result of mating between *C. neoformans* var *neoformans* serotypes A and D. *Filobasidiella bacillisporus* is the result of mating between *C. neoformans* var *gattii* serotypes B and C. Some strains of serotypes A and D can mate with strains of serotypes B and C. *Cryptococcus* species other than *C. neoformans* are, with rare exceptions, considered to be saprophytic and nonpathogenic. *Cryptococcus laurentii* has been associated with 15 cases of human disease. These cases mainly occurred in hosts with diseases or conditions that predisposed them to fungal infections.

S
I
d
e
6

HISTORY

S
I
d
e
7

History

- 1894
 - Isolated from tibial lesion of human patient by Busse and Buschke
 - Isolated from peach juice in Italy
- Most early cases associated with cancer patients
- 1905
 - First case of cryptococcal meningitis reported by Von Hansemann

In 1894, *Cryptococcus neoformans* was isolated from the tibial lesion of a patient in Germany by Busse and Buschke. It was also isolated from peach juice in Italy at that time. Many of the early case reports were associated with patients with cancer. The first case of cryptococcal meningitis was reported by Von Hansemann in 1905. Source: Mitchell TG, Perfect JR. Cryptococcosis in the era of AIDS--100 years after the discovery of *Cryptococcus neoformans*. Clin Microbiol Rev. 1995 Oct;8(4):515-48.

S
I
d
e
8

EPIDEMIOLOGY

S
I
j
d
e
g**Geographic Distribution**

- *C. neoformans* var *neoformans*
 - Found worldwide in soil
 - Serotype A most common in U.S.
- *C. neoformans* var *gattii*
 - Often found near eucalyptus trees
 - Tropical and sub-tropical areas



C. neoformans var. *neoformans* is found worldwide in the soil. Serotype A is the most common serotype in the U.S. *C. neoformans* var. *gattii* has been found around eucalyptus trees in tropical and sub-tropical areas including Australia, California and parts of South and Central America. It was also isolated from Vancouver Island, British Columbia during an outbreak of cryptococcosis. Photo: Eucalyptus *camaldulensis*. <http://www.public.asu.edu/~camartin/plants/Plant%20html%20files/eucalyptuscamaldulensis.html>.

S
I
j
d
e
1
0**Morbidity and Mortality:
Humans**

- *C. neoformans* var *neoformans*
 - General population
 - 0.4-1.3 cases/100,000 persons
 - Immunosuppressed people
 - AIDS patients
 - 2-7 cases/1,000 patients
 - Transplant recipients
 - 0.3-5.3 cases/100 patients
 - Mortality rate
 - 12-28% overall


Most cases of cryptococcosis are caused by *C. neoformans* var *neoformans* and occur in people with depressed cell-mediated immunity. AIDS patients and organ transplant recipients are particularly susceptible. Early in the AIDS epidemic, 5-8% of HIV-infected persons developed cryptococcosis; with more effective retroviral therapy, the incidence has decreased. The annual incidence of disease is currently 0.4-1.3 cases per 100,000 persons in the general population, 2 to 7 cases per 1,000 AIDS patients, and 0.3 to 5.3 cases per 100 transplant patients. Cases of cryptococcosis usually occur sporadically. The outcome of a *C. neoformans* infection depends on the health of the host, the form of the disease and the treatment. Healthy people seem to be exposed frequently without becoming ill. The overall mortality rate for cryptococcosis is 12-28%. In organ transplant patients, mortality rates from 20-100% have been reported. Species other than *C. neoformans* are very rarely pathogenic. Fifteen symptomatic *C. laurentii* infections have been documented in the literature, mainly in people with other diseases or factors that predisposed them to fungal infections.

S
I
j
d
e
1
1**Morbidity and Mortality:
Animals**

- Cases usually sporadic
- Cats most frequently affected
 - Immunosuppressed
 - Feline leukemia virus
 - Feline immunodeficiency virus
 - Untreated infections often fatal
- Birds carry organism in intestinal tract
 - Clinical disease rare

Cases of cryptococcosis usually occur sporadically. Clinical cryptococcosis is reported most often in cats. It is particularly common in cats that are immunosuppressed by feline leukemia virus or feline immunodeficiency virus infections. Cryptococcosis may also be more common in immunosuppressed dogs. The prognosis is guarded, especially in cases with CNS disease. Untreated infections are fatal. Cryptococcal mastitis in cattle is usually associated with treatment of the mammary gland for another condition. Fungal mastitis is usually mild, but some infections can cause the death of the cow. Cattle rarely recover spontaneously from cryptococcal mastitis. Clinical cryptococcosis is very rare in birds, but the organism can be carried transiently in the intestinal tract. *C. neoformans* has been isolated from the feces of 26% of canaries, 18% of carrier pigeons, 2% of budgerigars and 1% of psittacine birds.

S I d e 1 2	<p>TRANSMISSION</p>
--------------------------------	----------------------------

S I d e 1 3	<p style="text-align: center;">Transmission</p> <ul style="list-style-type: none"> • <i>C. neoformans</i> var <i>neoformans</i> <ul style="list-style-type: none"> - Grows naturally in environment <ul style="list-style-type: none"> • Soil saprophyte - Found in pigeons nests, droppings <ul style="list-style-type: none"> • Favorable growth environment • <i>C. neoformans</i> var <i>gattii</i> <ul style="list-style-type: none"> - Bark and plant debris under eucalyptus trees - Not associated with pigeons 	<p><i>C. neoformans</i> grows naturally in the environment. <i>C. neoformans</i> var <i>neoformans</i> is ubiquitous in the soil, where it grows as a saprophyte. It is common in old pigeon nests and around pigeon droppings; the bird droppings appear to create a favorable environment for its growth. It can also be isolated from numerous environmental sources including vegetables and fruit, house dust, air conditioners, air and sawdust. It can survive for months to years outside the host. <i>C. neoformans</i> var <i>gattii</i> is found in bark and plant debris under eucalyptus trees (the river red gum tree <i>Eucalyptus camaldulensis</i> and the forest red gum tree, <i>E. tereticornis</i>). It is also found in the air around these trees, particularly when they bloom in late spring. It is not associated with pigeon droppings. Recently, <i>C. neoformans</i> var <i>gattii</i> was isolated from trees and soil on Vancouver Island in British Columbia. Photo: Bark of <i>Eucalyptus camaldulensis</i>. http://www.public.asu.edu/~camartin/plants/Plant%20html%20files/eucalyptuscaldulensis.html.</p>
--------------------------------	--	---

S I d e 1 4	<p style="text-align: center;">Transmission</p> <ul style="list-style-type: none"> • Inhalation <ul style="list-style-type: none"> - Via environment • Reactivation of latent infection • Fomites <ul style="list-style-type: none"> - Mastitis in cattle <ul style="list-style-type: none"> • Contaminated syringes, cannulas, etc. • Animal-to-human and human-to-human transmission very rare 	<p>Transmission seems to be mainly by inhalation, but <i>C. neoformans</i> can also enter the body through the skin. Infections seem to be acquired mainly from the environment. Cryptococcosis can also result from the reactivation of a latent infection. Cryptococcal mastitis in cattle is usually associated with the treatment of the mammary gland for another condition. The organism may be introduced into the teat in contaminated syringes, cannulas or antibiotic preparations. It can also enter the mammary gland if the teat ends are not adequately cleaned before treatment. Cryptococcosis does not seem to be very contagious. There are no reports of transmission from mammalian animals to other animals or to humans. However, in one recent case, an immunosuppressed human probably acquired <i>C. neoformans</i> from the feces of an asymptomatic pet bird. Human-to-human transmission is extremely rare and has mainly occurred under unusual circumstances. Vertical transmission was recently described, when a HIV-positive mother with peripartum cryptococcal meningitis infected her newborn.</p>
--------------------------------	---	--

S
I
d
e
1
5

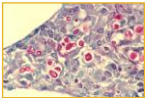
DISEASE IN HUMANS

S
I
d
e
1
6

- Disease in Humans**
- Spectrum of disease
 - *C. neoformans* var *neoformans*
 - Opportunist
 - Immunosuppressed patients
 - *C. neoformans* var *gattii*
 - Immunocompetent people
 - Initial infection usually in lungs

In humans, the spectrum of disease varies from asymptomatic colonization of the airways to meningitis and other serious diseases. *C. neoformans* var *neoformans* is an opportunist that mainly causes disease in immunosuppressed patients. In these patients, there may be little inflammation and the symptoms can be mild even with extensive disease. Patients infected with *C. neoformans* var *gattii* are usually immunocompetent. The initial infection usually occurs in the lungs.

S
I
d
e
1
7

- Disease in Humans**
- Pulmonary cryptococcosis
 - Often asymptomatic
 - Coughing, pleuritic chest pain may occur
 - Rarely fatal
 - Progressive disease most common in immunocompromised
 - Disseminated disease
 - Often first sign of cryptococcosis
- 

Pulmonary cryptococcosis can be accompanied by respiratory disease or radiological abnormalities, but most infections (in both immunocompetent and immunosuppressed hosts) are asymptomatic. In immunocompetent patients, *C. neoformans* can cause coughing and pleuritic chest pain. Most symptomatic infections are self-limited, but chronic infections and rare cases of fatal cryptococcal pneumonia have been reported. In most healthy people, the infection remains confined to the lungs. In immunosuppressed patients, the symptoms of pulmonary cryptococcosis may include fever, malaise, coughing, pleuritic pain, dyspnea, headache, weight loss and rarely, hemoptysis. After the initial pulmonary infection, *C. neoformans* may spread to other organ systems, particularly in immunosuppressed patients. The organism can disseminate even if the pulmonary infection was asymptomatic. In many patients, the first sign of cryptococcosis is disseminated disease.

[Photo: Cryptococcosis of lung in patient with AIDS. Mucicarmin stain. Histopathology of lung shows widened alveolar septum containing a few inflammatory cells and numerous yeasts of *Cryptococcus neoformans*. The inner layer of the yeast capsule stains red. Source: CDC Public Health Image Library]

S
I
d
e
1
8

- Disease in Humans**
- Disseminated disease
 - CNS infections most common
 - Meningitis, meningoencephalitis
 - Headache, nausea, vomiting
 - Changes in mental status
 - Untreated infections often fatal
 - Subacute presentations common in AIDS patients
 - May have few symptoms or exhibit nonspecific signs

The most common form of disseminated cryptococcosis is CNS disease, particularly subacute or chronic meningitis and meningoencephalitis. The symptoms may include a headache, nausea, vomiting and changes in mental status such as personality changes, lethargy or confusion. A fever and stiff neck are less common signs. Seizures, ataxia, aphasia, hearing defects, blurred vision, photophobia, other motor or sensory deficits and coma may also be seen. Elevated CSF pressure can lead to hydrocephalus and dementia. Untreated CNS infections are fatal in days to months. Either meningitis/ meningoencephalitis or focal mass lesions (cryptococcomas) can occur in immunocompetent patients.

Cryptococcomas are often associated with focal neurologic signs. In AIDS patients, the presentation is typically subacute. In the initial stages, these patients may have few symptoms or only nonspecific signs. Common symptoms are a headache and fever and, less often, altered mental status. Focal CNS disease is uncommon in AIDS patients.

S
I
j
d
e
1
9

Disease in Humans


- Additional disease forms
 - Ocular lesions
 - Optic neuritis, chorioretinitis, endophthalmitis
 - Skin lesions
 - Papules, vesicles, bullae, ulcers, etc.
 - Cellulitis
 - Organ transplant recipients
 - Other
 - Involvement of bone, other organs

C. neoformans can cause ocular lesions including optic neuritis, chorioretinitis and endophthalmitis. *C. neoformans* can cause a wide variety of skin lesions including papules, vesicles, bullae, ulcers, purpura, subcutaneous tumor-like masses and abscesses. The lesions can mimic other diseases including acne, lipomas, syphilis, tuberculosis and basal cell carcinoma. AIDS patients may have umbilicated papules that resemble molluscum contagiosum. Cellulitis is common in organ transplant recipients. Skin disease can occur alone in healthy people, but in immunosuppressed patients it suggests disseminated disease. Less frequent syndromes include osteomyelitis, septic arthritis, myocarditis, hepatitis, peritonitis, renal abscesses, prostatitis, myositis and gastroenteritis. In AIDS patients, invasion of the adrenal glands can cause adrenal insufficiency.

S
I
j
d
e
2
0


Diagnosis in Humans

- Detection in tissues or fluids
 - Methods
 - Direct observation
 - Culture
 - Imaging (CT, MRI, X-ray)
 - Specimens
 - CSF, blood, sputum, urine, others
 - Yeast characteristics
 - Encapsulated, round to oval, clear halo



Cryptococcosis is usually diagnosed by detection of the organism in tissues or fluids. In CNS disease, *C. neoformans* may be found in the CSF. *C. neoformans* can sometimes be found in clinical samples by direct observation. This organism is an encapsulated 4 to 6 mm, round to oval yeast. It is surrounded by a halo-like capsule that stains strongly with Mayer's mucicarmine. In an India ink preparation, yeast cells surrounded by a clear halo (the capsule) may be seen; unless budding is observed, the organisms can be confused with fat droplets or other artifacts. *C. neoformans* can be identified in the tissues by immunofluorescence. A definitive diagnosis can be obtained by culturing the blood, CSF, sputum, bronchoalveolar lavage washings or urine. A latex agglutination test or ELISA can detect *C. neoformans* capsular antigens in blood, CSF or urine. This test may not be positive if the disease is localized (e.g. in the lungs) and false positive reactions can be seen. Other diagnostic tests include CT and MRI in patients with CNS disease, and x-rays in patients with pulmonary disease. Serology is not considered to be useful in humans, as antibodies are often found in healthy people.

[Photo: Culture of *Cryptococcus neoformans*. Source: Mycology Online, The University of Adelaide at http://www.mycology.adelaide.edu.au/Fungal_Descriptions/Yeasts/Cryptococcus/C_neoformans.html]

<p>S I d e 2 1</p>	<p style="text-align: center;">Treatment in Humans</p> <ul style="list-style-type: none"> • Anti-fungals <ul style="list-style-type: none"> - Amphotericin B, fluconazole, others - Long term therapy may be required in AIDS patients • <i>C. neoformans</i> var <i>gattii</i> <ul style="list-style-type: none"> - Infections respond slowly to treatment 	<p>Cryptococcosis can be treated with amphotericin B, 5- fluorocytosine, fluconazole, itraconazole and ketoconazole. After the initial therapy, long term or lifelong treatment may be required in AIDS patients. Immunocompetent patients may or may not be treated if the infection is confined to the lungs, as these infections are usually self-limiting. <i>C. neoformans</i> var <i>gattii</i> infections often respond slowly to treatment. There is no standard treatment for <i>C. laurentii</i>, but some cases were treated successfully with amphotericin B.</p>		
<p>S I d e 2 2</p>	<p style="text-align: center;">DISEASE IN ANIMALS</p>			
<p>S I d e 2 3</p>	<p style="text-align: center;">Species Affected</p> <table border="0"> <tr> <td> <ul style="list-style-type: none"> • Cats • Cattle • Dogs • Ferrets • Guinea Pigs • Horses • Sheep • Goats • Llamas </td> <td> <ul style="list-style-type: none"> • Foxes • Mink • Cheetahs • Gazelles • Koalas • Wallabies • Porpoises • Non-human primates </td> </tr> </table>	<ul style="list-style-type: none"> • Cats • Cattle • Dogs • Ferrets • Guinea Pigs • Horses • Sheep • Goats • Llamas 	<ul style="list-style-type: none"> • Foxes • Mink • Cheetahs • Gazelles • Koalas • Wallabies • Porpoises • Non-human primates 	<p>Clinical cryptococcosis is most often found in cats. Outbreaks of cryptococcal mastitis and pneumonia have been described in cattle. Clinical cases have also been reported in dogs, ferrets, guinea pigs, horses, sheep, goats, pigs, llamas, foxes, mink, cheetahs, gazelles, koalas, wallabies, porpoises, non-human primates and other animals. <i>C. neoformans</i> can be isolated from asymptomatic mammals. <i>C. neoformans</i> can be found in the feces of birds including canaries, budgerigars, psittacine birds, chickens, sparrows, starlings, skylarks, pigeons and turtledoves. The presence of this organism in the feces can be due to a transient asymptomatic intestinal infection, or to the inoculation of the feces with organisms carried on the beaks or feet. Clinical infections in birds are very rare.</p>
<ul style="list-style-type: none"> • Cats • Cattle • Dogs • Ferrets • Guinea Pigs • Horses • Sheep • Goats • Llamas 	<ul style="list-style-type: none"> • Foxes • Mink • Cheetahs • Gazelles • Koalas • Wallabies • Porpoises • Non-human primates 			
<p>S I d e 2 4</p>	<p style="text-align: center;">Clinical Signs: Cats</p> <ul style="list-style-type: none"> • Upper respiratory <ul style="list-style-type: none"> - Most common form of disease in cats - Sneezing, snoring, dyspnea, nasal discharge, nasal polyps • Skin lesions <ul style="list-style-type: none"> - Firm nodular lesions - Face often affected • CNS • Other 	<p>In cats, disease may be seen in a single organ system or many. Upper respiratory disease (unilateral or bilateral chronic rhinitis or sinusitis) is the most common form of cryptococcosis in cats. The symptoms may include sneezing, snoring or snorting, dyspnea, or a mucopurulent or serosanguineous nasal discharge. Polyp-like masses may protrude from one or both nostrils. Pulmonary symptoms are uncommon. <i>C. neoformans</i> can cause skin lesions, particularly on the face. Typically, there are one or more firm, nodular, cutaneous or subcutaneous swellings on the head, particularly the bridge of the nose, side of the face, upper lip or nostril. Some lesions may ulcerate. There is little or no pruritus. Fluctuant or firm papules and nodules may also occur on other parts of the body; generalized skin disease suggests disseminated cryptococcosis. Central nervous system (CNS) disease, due either to a focal mass lesion or diffuse neurologic disease, is also common. Neurologic signs may be mild or severe, and can include a change in temperament, depression, disorientation, ataxia, paresis or paralysis, seizures, circling, abnormal pupillary responses, anisocoria and blindness. <i>C. neoformans</i> can also invade other organs and less common</p>		

presentations, including osteomyelitis, may be seen.

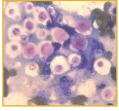
[Photo: Cat. There are multiple foci of ulcerative dermatitis; the rostral lesion likely resulted from extension of cryptococcal rhinitis through the facial bones. Dr. J. Noxon, Iowa State University/CFSPH]

S I j d e 2 5	<p style="text-align: center;">Clinical Signs: Dogs</p> <ul style="list-style-type: none"> • Disseminated disease <ul style="list-style-type: none"> - Neurologic disease most common form of cryptococcosis in dogs • Ocular <ul style="list-style-type: none"> - Chorioretinitis, optic neuritis • Other organs also affected <ul style="list-style-type: none"> - Nasal cavity rarely affected 	<p>Most dogs have severe disseminated disease. Neurologic disease is the most common form in dogs and resembles the disease in cats. Ocular lesions are also common and may include granulomatous chorioretinitis and optic neuritis. Disease can also occur in other organs, but cryptococcosis rarely affects the nasal cavity in dogs.</p>
S I j d e 2 6	<p style="text-align: center;">Clinical Signs: Other Animals</p> <ul style="list-style-type: none"> • Cows: mastitis • Sheep and goats: pulmonary disease • Horses: CNS, pulmonary, other • Birds <ul style="list-style-type: none"> - Disease rare <ul style="list-style-type: none"> • Rhinitis and sinusitis may occur - Shed organism in feces 	<p>Outbreaks of cryptococcal mastitis occur in cows. The symptoms may include anorexia, decreased milk production, and enlargement of the supramammary lymph nodes. The affected quarters are usually swollen and firm. The milk may be viscid, mucoid and grayish-white, or it may be watery with flakes. Pulmonary disease and mastitis have been described in sheep and goats. Syndromes that have been reported in horses include meningoencephalitis, pulmonary disease, upper respiratory disease affecting the frontal sinuses and paraorbital area, and abortions. Obstructive growths in the nasal cavities are the most common presentation. Cryptococcosis is very rare in birds; mycotic rhinitis and sinusitis have been described. However, the organism can be found in their feces especially in pigeons.</p>
S I j d e 2 7	<p style="text-align: center;">Post Mortem Lesions</p> <ul style="list-style-type: none"> • Granulomas or gelatinous masses <ul style="list-style-type: none"> - Minimal inflammation - Any organ system <ul style="list-style-type: none"> • Lungs, kidney, lymph nodes, spleen, liver • CNS involvement <ul style="list-style-type: none"> - Meninges congested and thickened - Brain and spinal cord abscesses • Ocular lesions 	<p>The gross lesions may appear either as granulomas or as gelatinous masses with minimal inflammation. In cats, lesions can occur in any organ system. Often, there is a viscous exudate in the nasal passages and sinuses, and/or small gelatinous nodules scattered on the viscera of the abdominal and thoracic cavities. In cases with CNS involvement, the meninges may be congested and thickened. They sometimes have a cloudy, gelatinous appearance, and they may be covered by a scant mucoid exudate. Abscesses may be found in the brain or spinal cord. Ocular lesions including chorioretinitis or panophthalmitis can also be seen.</p>

S
I
d
e
2
8

Diagnosis in Animals

- Detection in tissues or fluids
 - Methods
 - Direct observation
 - Culture
 - Serology
 - Specimens
 - CSF, biopsies, impression smears, aspirates
 - Yeast characteristics
 - Encapsulated, round to oval, clear halo



Cryptococcosis is usually diagnosed by detecting *C. neoformans* in biopsies, impression smears, aspirates, or swabs of nasal secretions or skin exudates. In cases of CNS disease, *C. neoformans* may be found in the cerebrospinal fluid (CSF). *C. neoformans* can sometimes be found in clinical samples by direct observation. This organism is an encapsulated 4 to 6 mm, round to oval yeast. It is surrounded by a halo-like capsule that stains strongly with Mayer’s mucicarmine. In an India ink preparation, yeast cells surrounded by a clear halo (the capsule) may be seen; unless budding is observed, the organisms can be confused with fat droplets or other artifacts. *C. neoformans* can be identified in the tissues by immunofluorescence. A definitive diagnosis can be obtained by culture. Although *C. neoformans* grows on most media, growth is best on fungal media such as Sabaraud’s dextrose agar without cycloheximide. A latex agglutination test or ELISA can detect *C. neoformans* capsular antigens in blood, CSF or urine. Serology may be useful in some cases; however, large amounts of capsular antigen in the circulation appear to tie up antibodies. Cats with clinical disease seldom have positive titers. Serologic tests used in cats include complement fixation, immunodiffusion, indirect immunofluorescence and tube agglutination.

[Photo: This aspirate from a cutaneous lesion in a cat contains numerous *Cryptococcus neoformans* yeast organisms surrounded by a non-staining capsule. Narrow-based budding can be seen. Dr. C. Andreasen, Iowa State University, College of Veterinary Medicine, Department of Veterinary Pathology/CFSPH]

S
I
d
e
2
9


Treatment in Animals

- Anti-fungals
 - Amphotericin B
 - Flucytosine
 - Itraconazole
 - Fluconazole

Cryptococcosis can be treated with amphotericin B, flucytosine, itraconazole and fluconazole. Amphotericin B and flucytosine are often used in combination. A combination of ketoconazole and itraconazole has been effective in some experimentally infected cats, including animals with neurologic disease.

S
I
d
e
3
0

PREVENTION AND CONTROL

<p>S I d e 3 1</p>	<p style="text-align: center;">Prevention and Control</p> <ul style="list-style-type: none"> • Environmental exposures <ul style="list-style-type: none"> - Difficult to prevent • <i>C. neoformans</i> var <i>neoformans</i> <ul style="list-style-type: none"> - Avoid pigeon droppings <ul style="list-style-type: none"> • Carefully remove from environment • <i>C. neoformans</i> var <i>gattii</i> <ul style="list-style-type: none"> - Avoid eucalyptus trees <ul style="list-style-type: none"> • Other exposures sources exist 	<p>Prevention of environmental exposure is difficult, as <i>C. neoformans</i> is ubiquitous in the environment. Avoidance and/ or environmental control of pigeon droppings may be beneficial in preventing disease due to <i>C. neoformans</i> var <i>neoformans</i>. Removal of pigeon droppings should be preceded by chemical decontamination or wetting with water or oil to decrease aerosolization. Pigeon droppings can remain infectious for up to 2 years. <i>C. neoformans</i> var <i>gattii</i> infections are mainly associated with exposure to eucalyptus trees, particularly during the period when they bloom (November to February). Avoidance of these trees may reduce the risk of exposure but other sources of <i>C. neoformans</i> var <i>gattii</i> also seem to exist. [Photo: Two pigeons. Source: Wikimedia Commons]</p>
<p>S I d e 3 2</p>	<p style="text-align: center;">Prevention and Control</p> <ul style="list-style-type: none"> • Animal-associated exposures <ul style="list-style-type: none"> - <i>C. neoformans</i> var <i>neoformans</i> carried by pet birds in intestinal tract <ul style="list-style-type: none"> • Use care when cleaning cages - No mammal-to-human cases reported <ul style="list-style-type: none"> • Use care when handling infected animals - Immunosuppressed people most at risk <ul style="list-style-type: none"> • Anti-fungals may be used for prophylaxis 	<p>Pet birds can carry <i>C. neoformans</i> var <i>neoformans</i> asymptotically in the intestinal tract. The organisms are found mainly in the feces and can be aerosolized by sweeping, cleaning the cage and similar activities. Animals that may be sources of <i>C. neoformans</i> should be treated with caution, particularly by people who are immunosuppressed. Although no cases of mammal-to-human transmission have been reported, people handling animals with cryptococcosis should also use appropriate precautions and wear protective clothing such as gloves and a mask. Cages and litter boxes should also be decontaminated regularly. Fluconazole has been used for prophylaxis in AIDS patients.</p>
<p>S I d e 3 3</p>	<p style="text-align: center;">Prevention and Control</p> <ul style="list-style-type: none"> • Cryptococcal mastitis <ul style="list-style-type: none"> - Usually associated with treatment of mammary gland for another condition - Take care not to contaminate syringes, cannulas, or antibiotic preparations - Clean teat ends before treatment 	<p>Cryptococcal mastitis in cattle is usually associated with the treatment of the mammary gland for another condition. Care should be taken not to contaminate syringes, cannulas or antibiotic preparations with <i>C. neoformans</i> from soil or other sources. The teat ends should also be adequately prepared before treatment.</p>
<p>S I d e 3 4</p>	<p style="text-align: center;">Additional Resources</p> <ul style="list-style-type: none"> • Center for Food Security and Public Health <ul style="list-style-type: none"> - www.cfsph.iastate.edu • CDC <ul style="list-style-type: none"> - http://www.cdc.gov/fungal/cryptococcosis-neoformans/ - http://www.cdc.gov/fungal/cryptococcosis-gattii/ <small>Center for Food Security and Public Health, Iowa State University, 2012</small>	
<p>S I d e 3 5</p>	<p style="text-align: center;">Acknowledgments</p> <p>Development of this presentation was made possible through grants provided to the Center for Food Security and Public Health at Iowa State University, College of Veterinary Medicine from the Centers for Disease Control and Prevention, the U.S. Department of Agriculture, the Iowa Homeland Security and Emergency Management Division, and the Multi-State Partnership for Security in Agriculture.</p> <p><small>Authors: Kerry Leedom Larson, DVM, MPH, PhD, DACVPM; Anna Rovid Spickler, DVM, PhD Reviewer: Glenda Dvorak, DVM, MPH, DACVPM</small></p>	<p>Last updated: September 2012</p>